

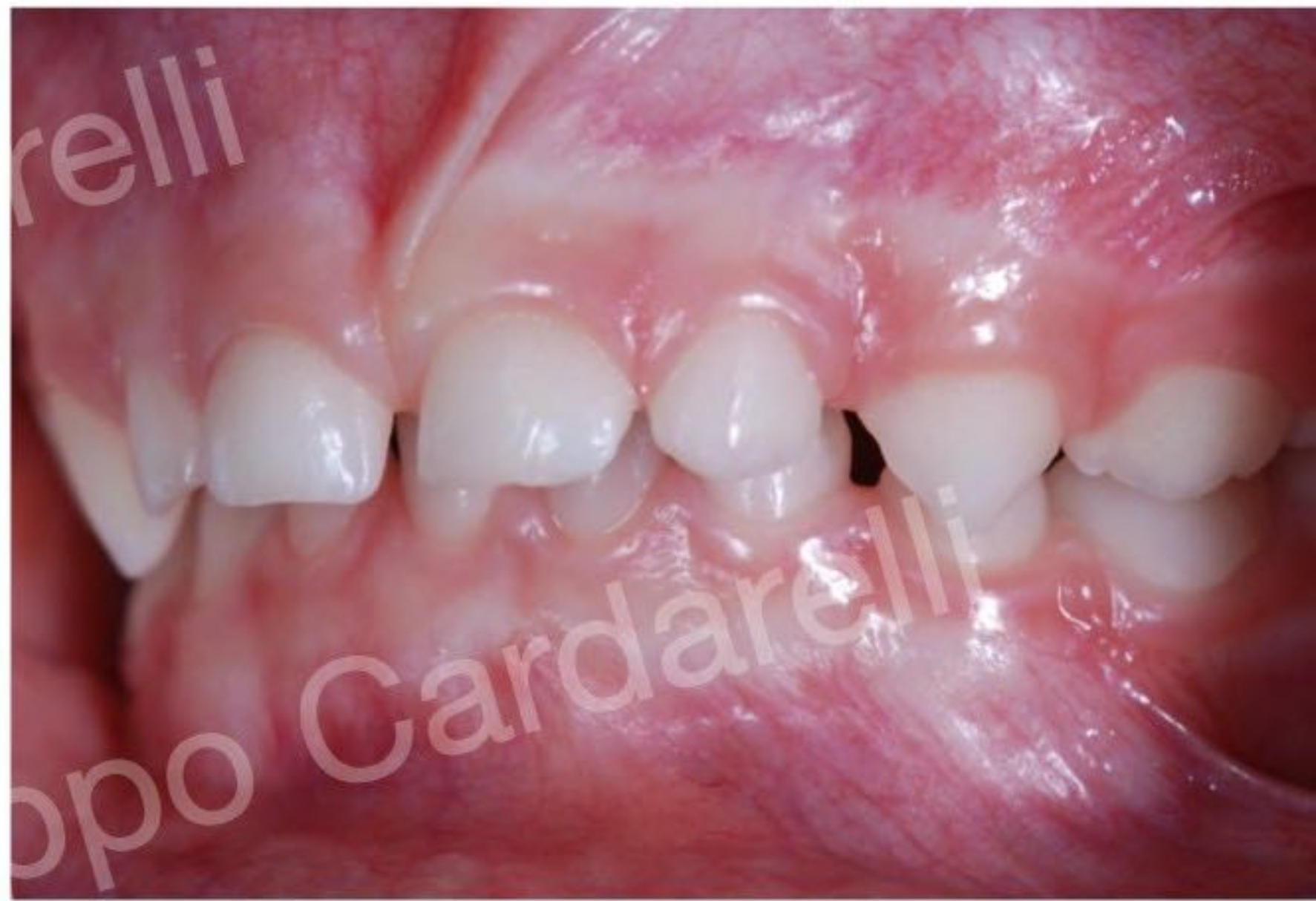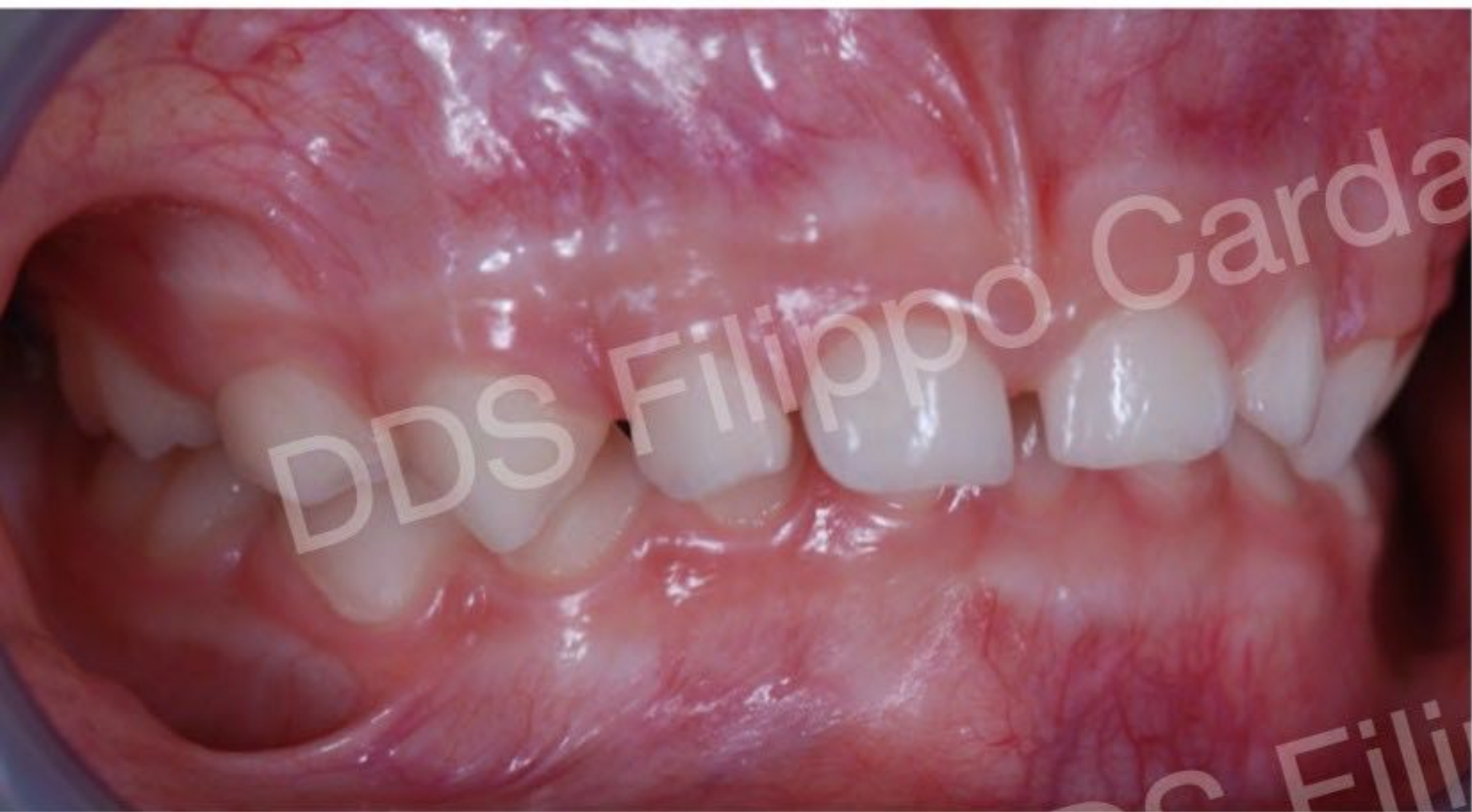DDS Filippo Cardarelli
Dentist
Specialist in Orthodontics
University of Milan



Class IInd Deep Bite

Patient 5 years old, II Skeletal Class deep bite from spoiled habit (protracted finger sucking). Malocclusion is characterized by contraction of the upper arch with reduced space for eruption of permanent teeth. The therapeutic sequence involves the following steps :

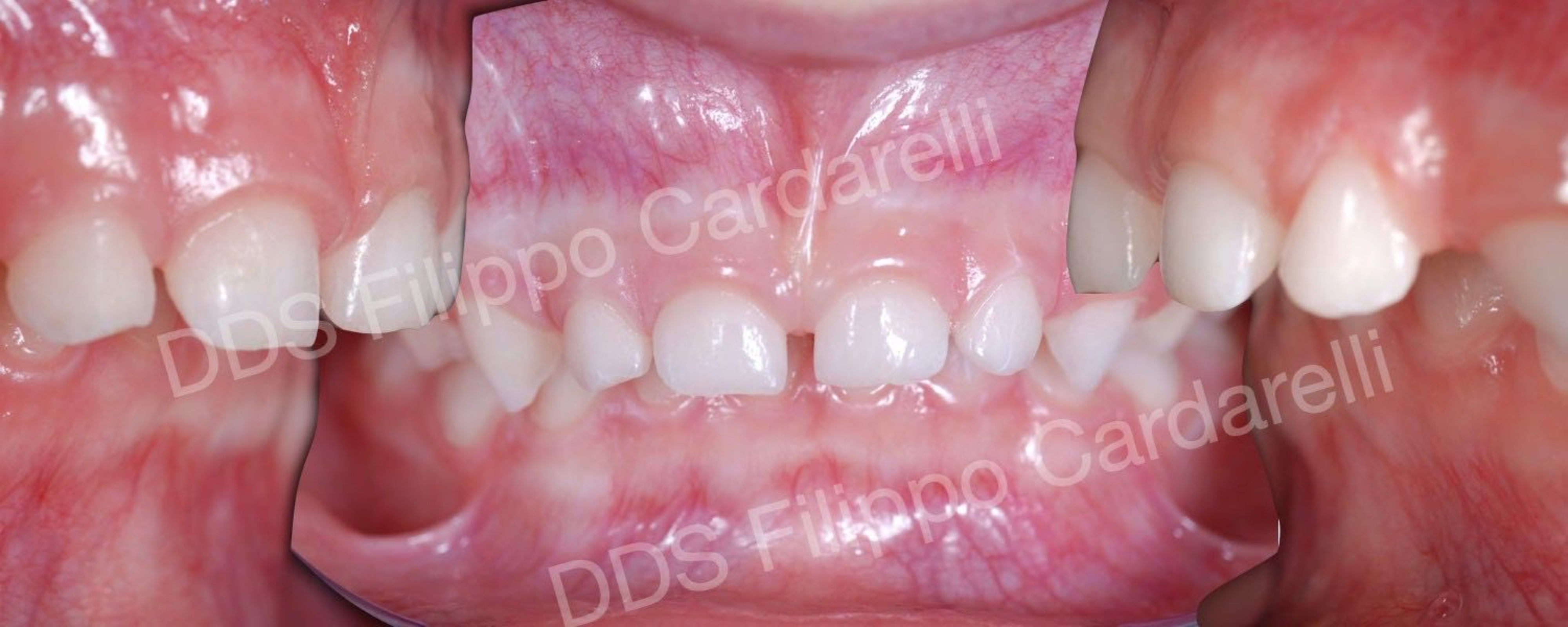- motivation
- logopedia
- elastodontic therapy with 2 appliances

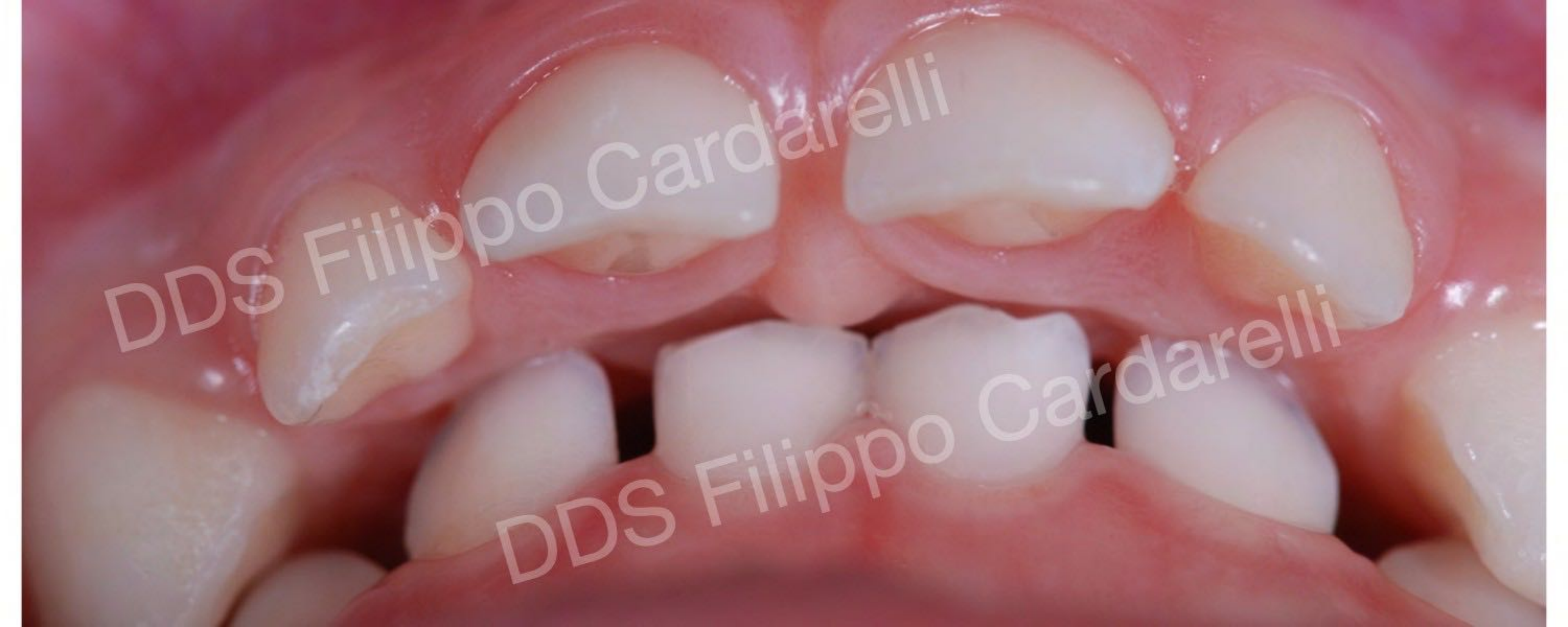


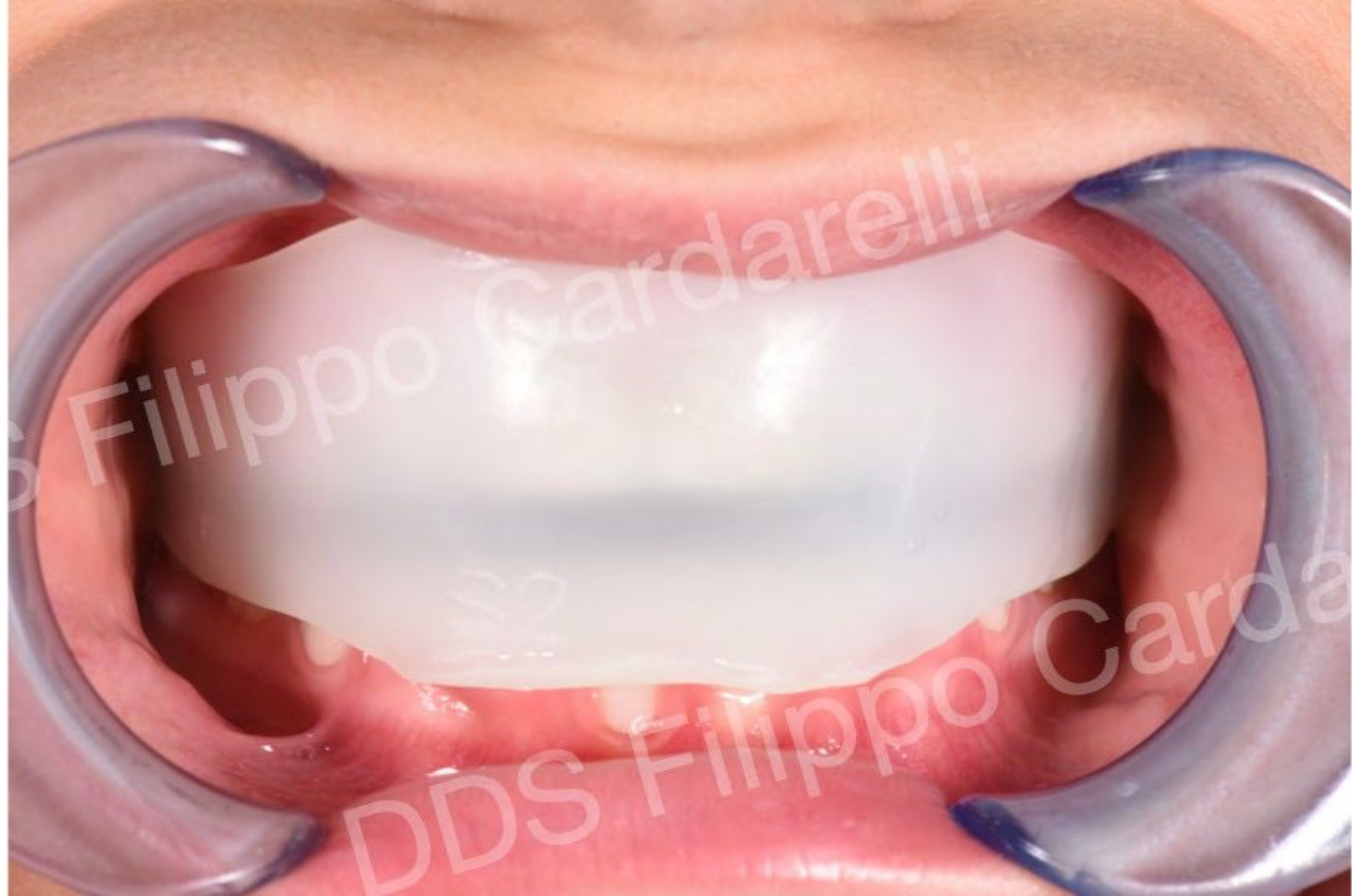
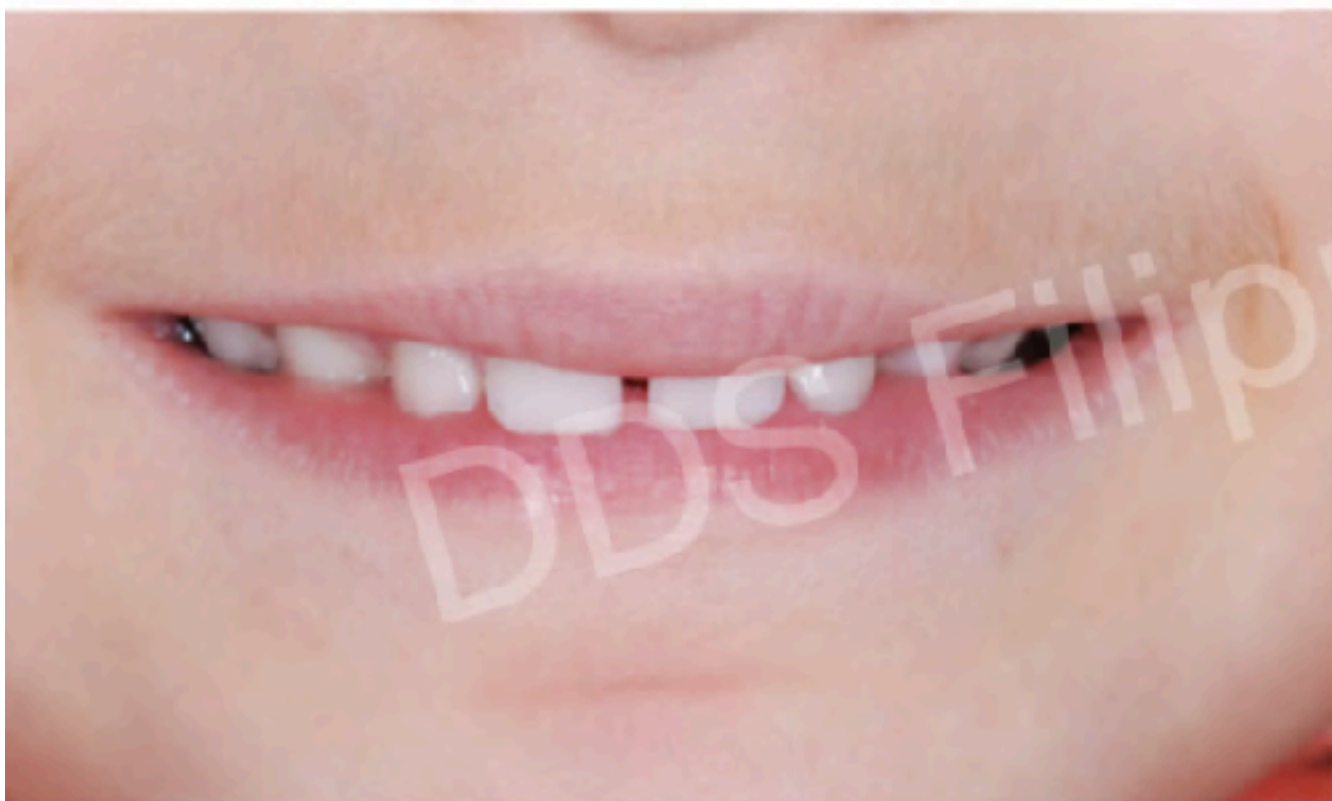DDS Filippo Cardarelli

DDS Filippo Cardarelli

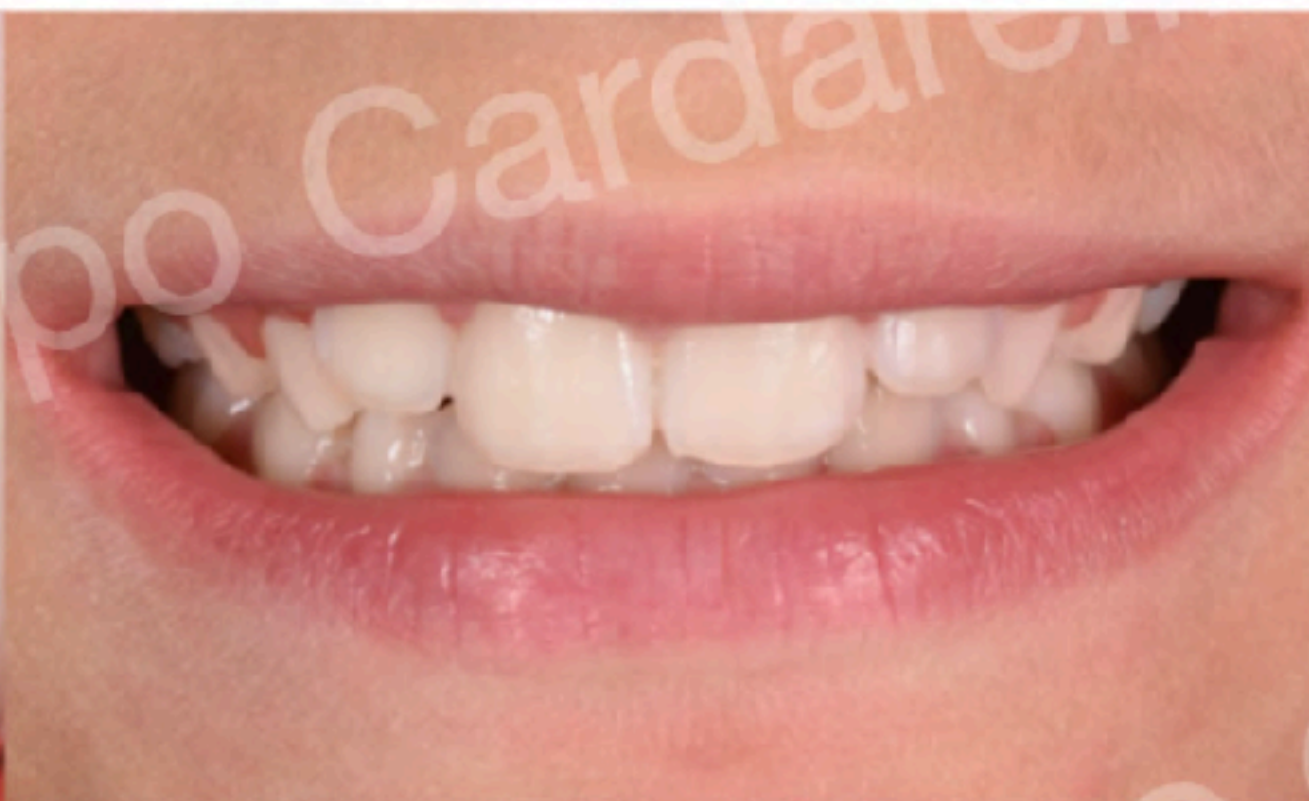




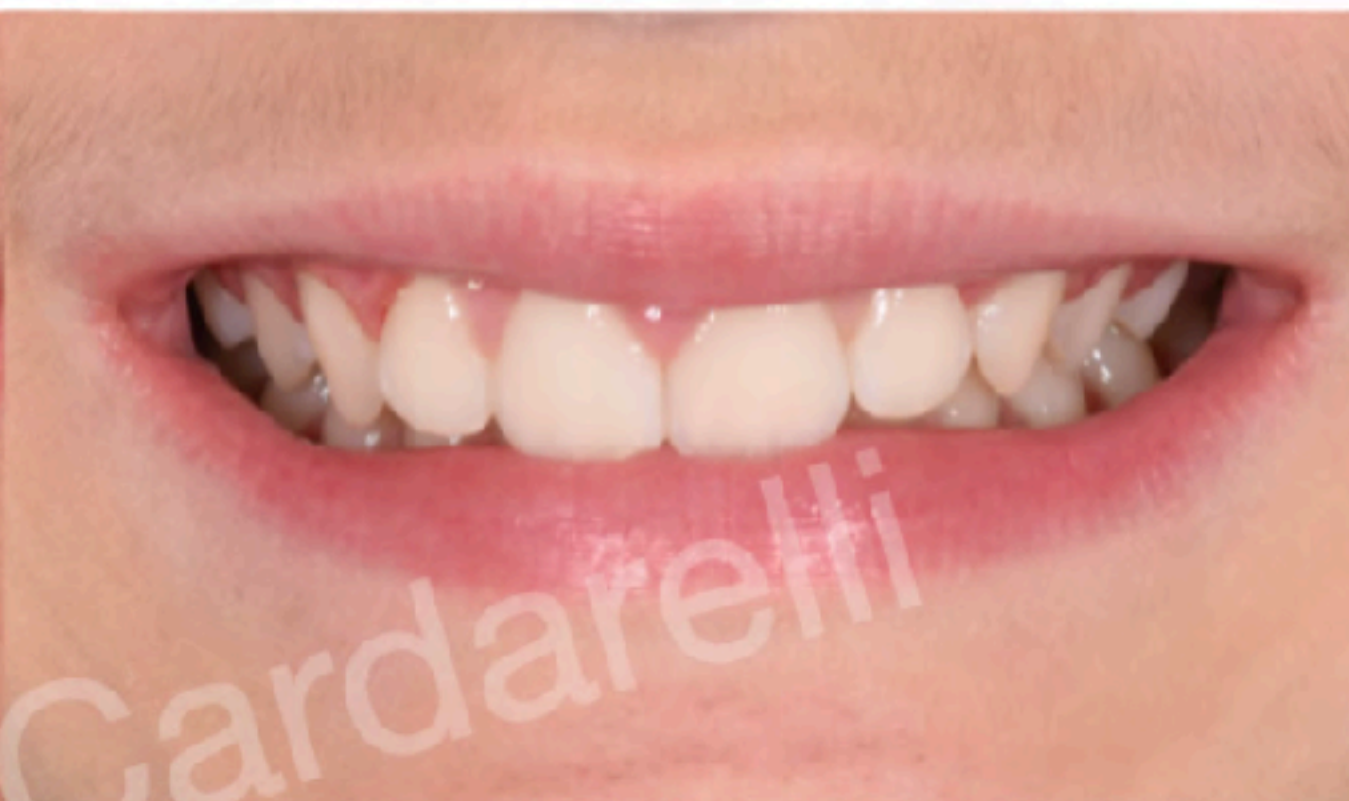


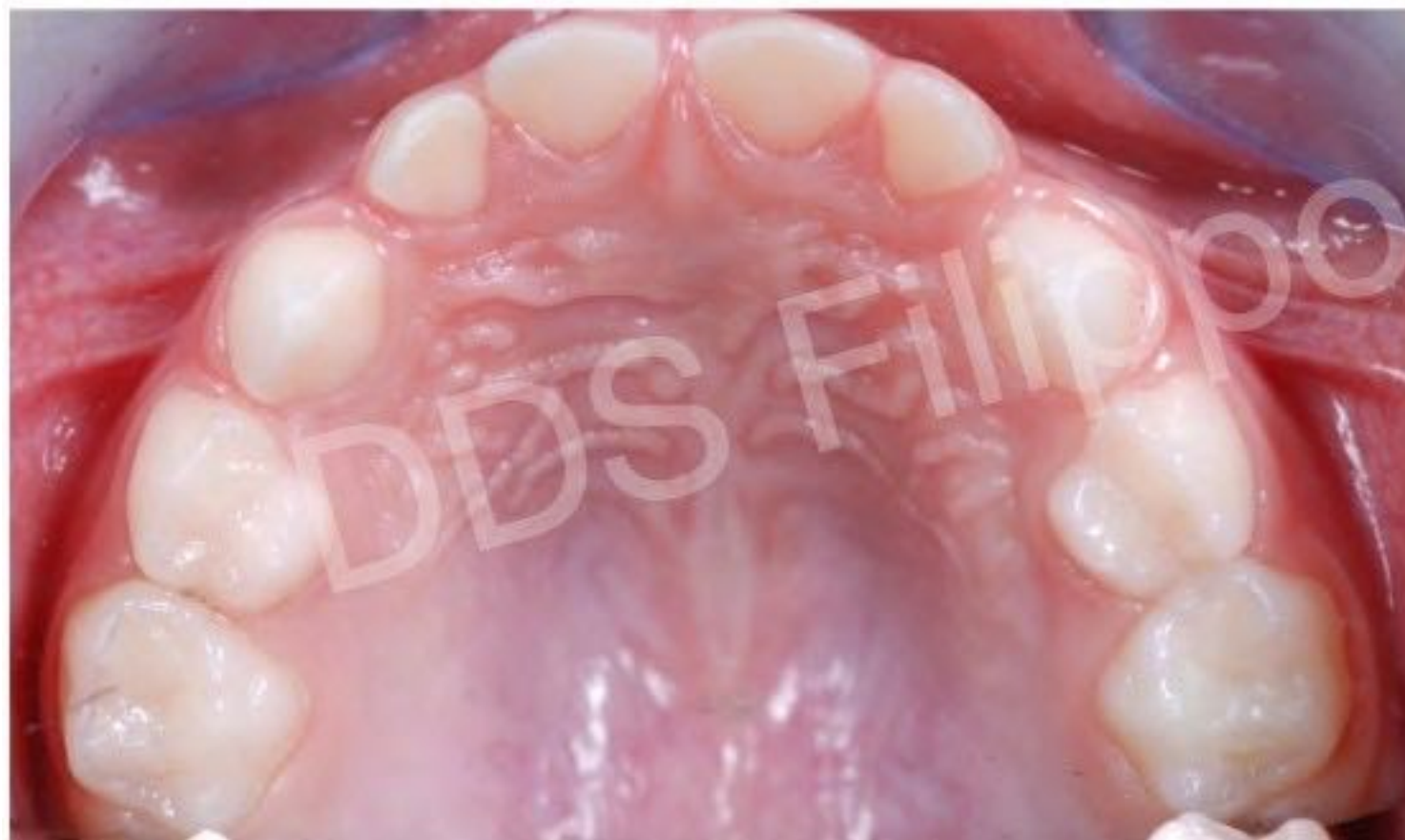12/15



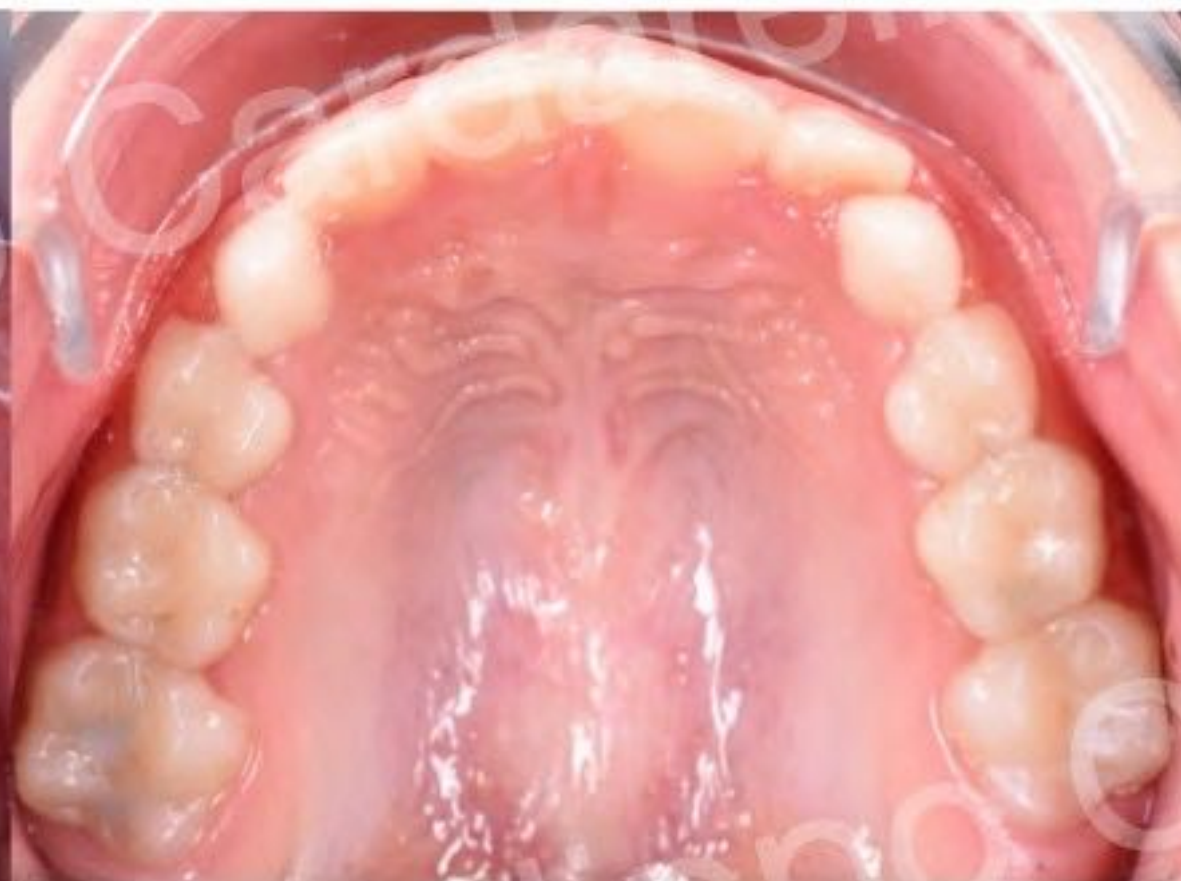9/18



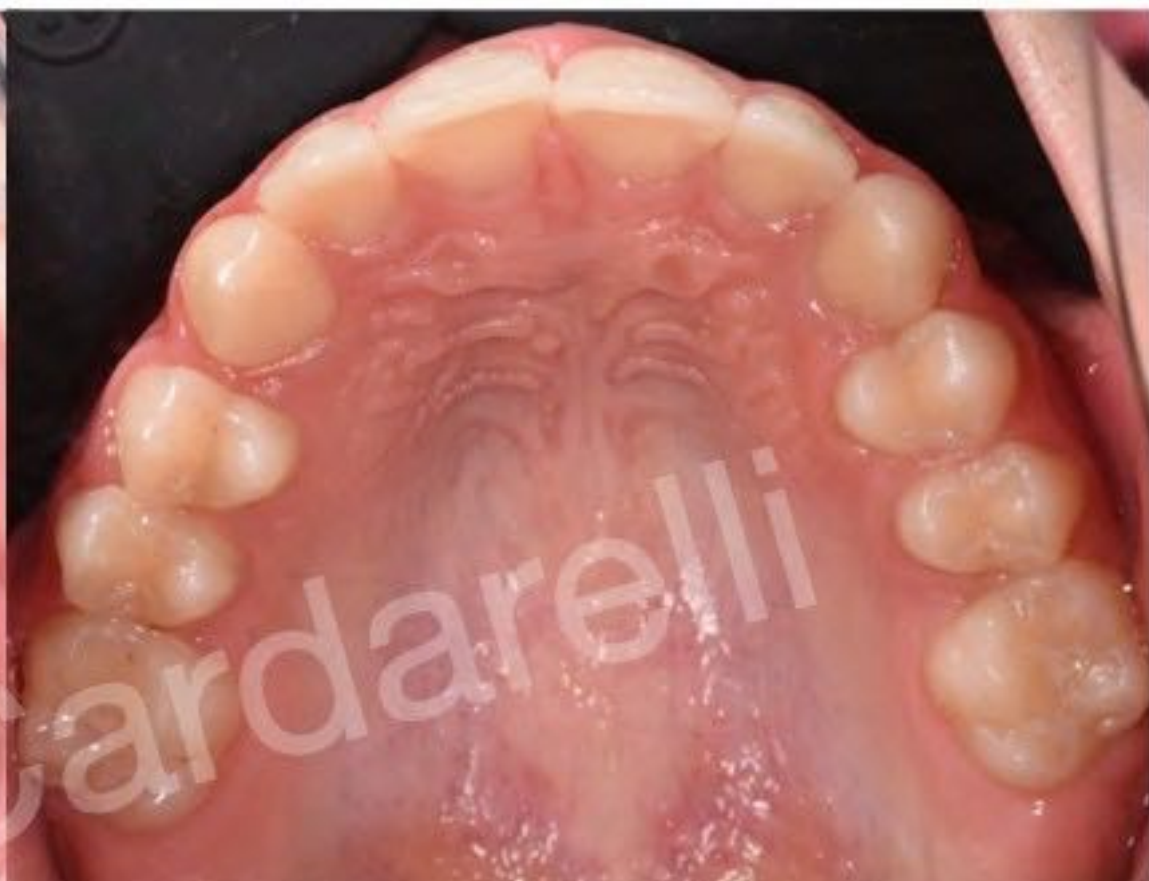02/21



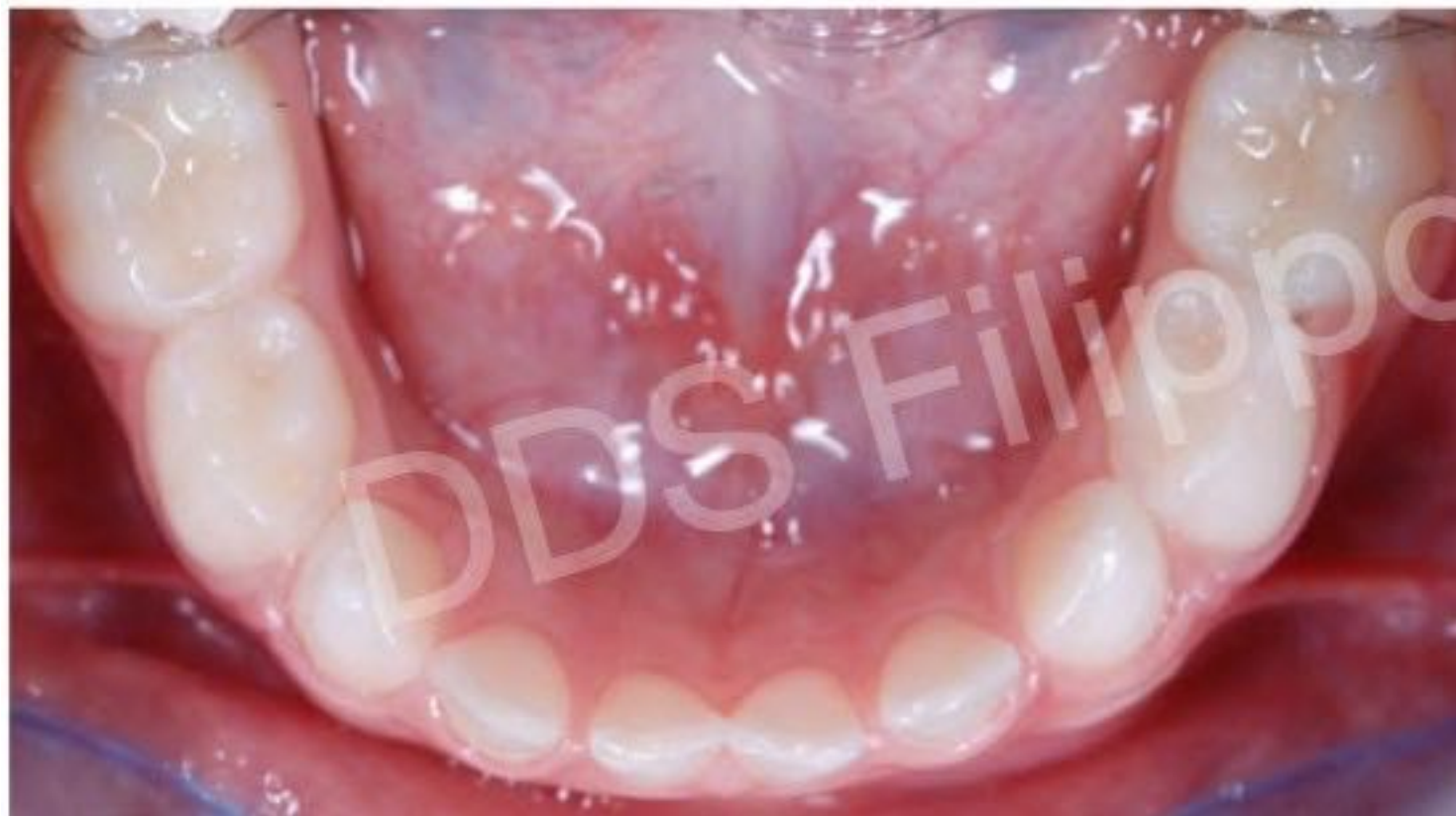12/15



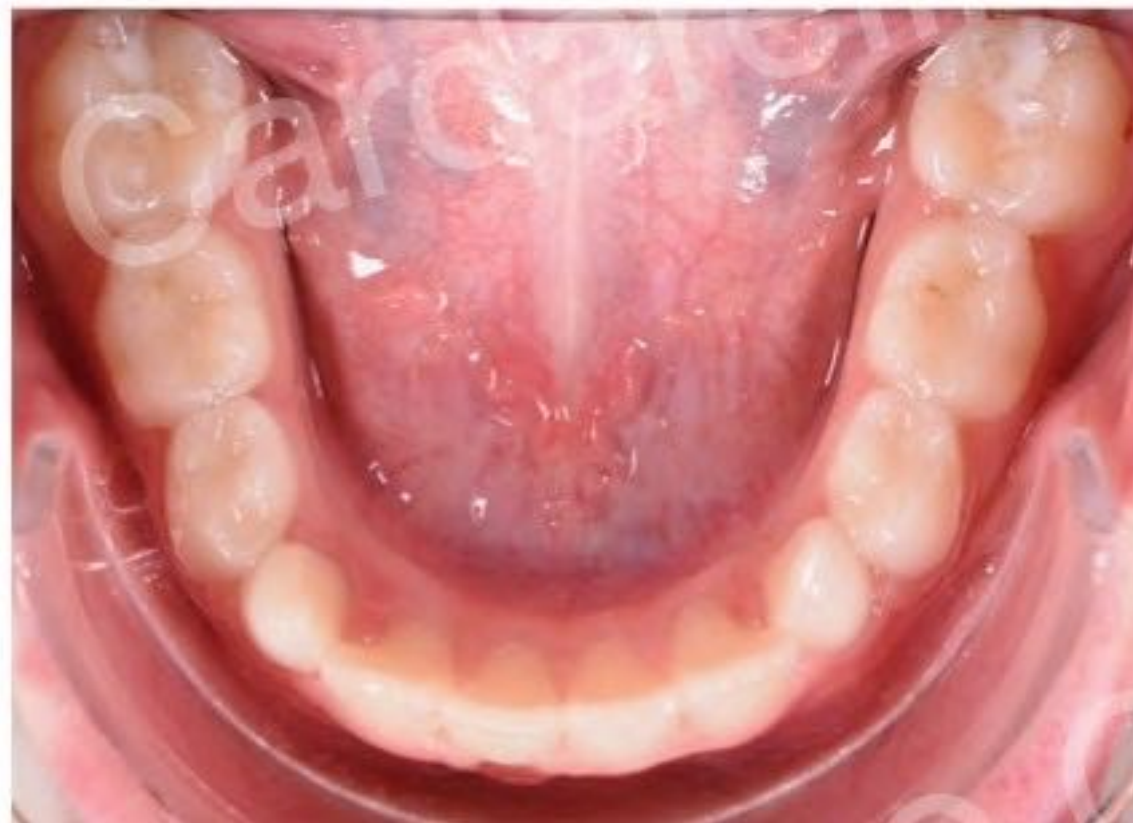9/18



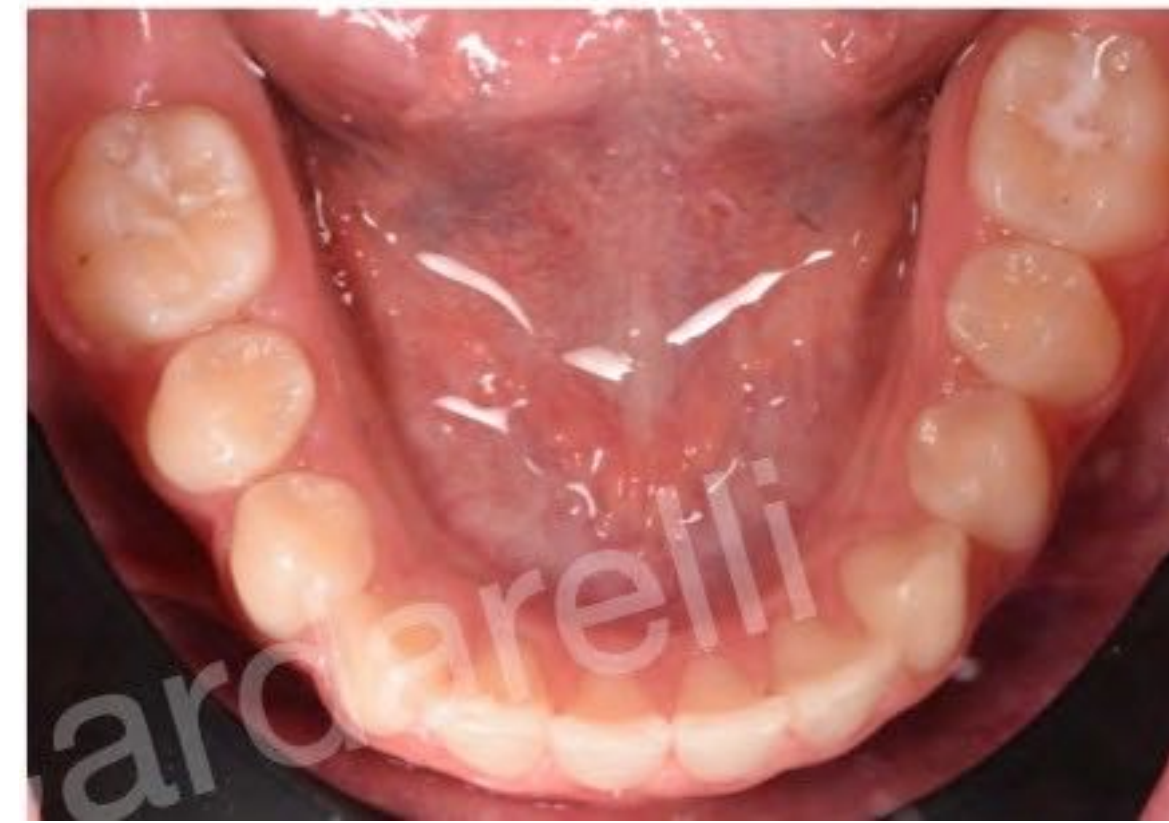02/21



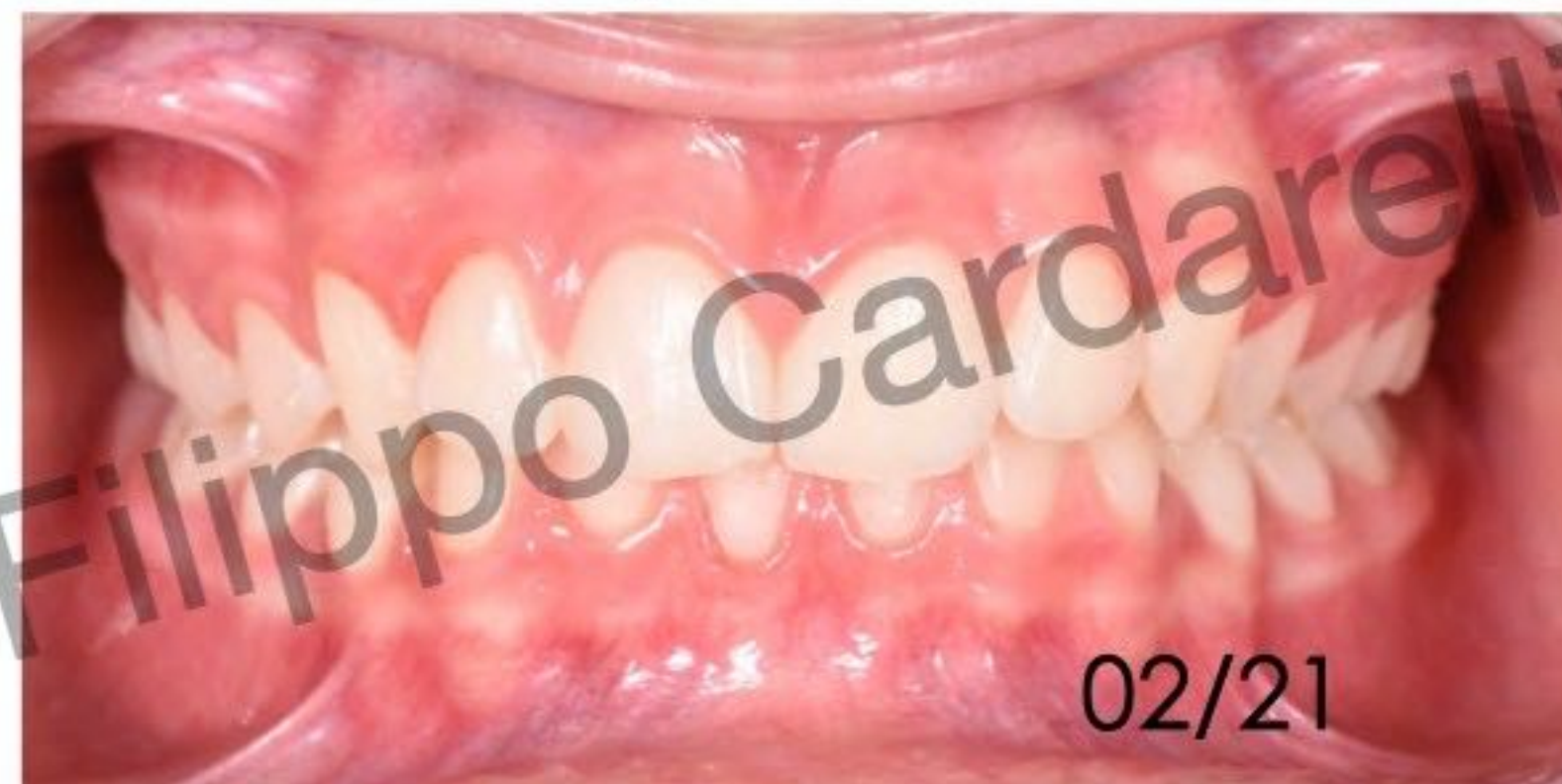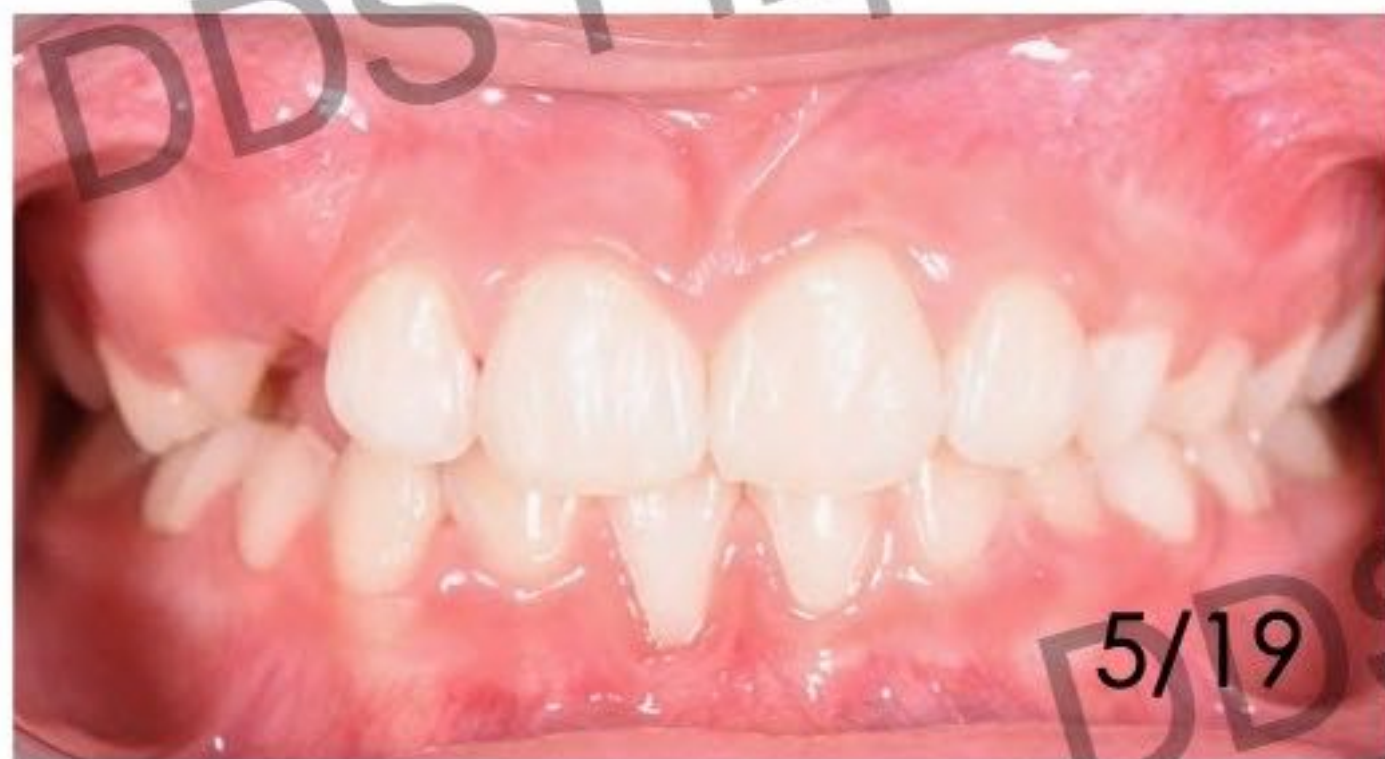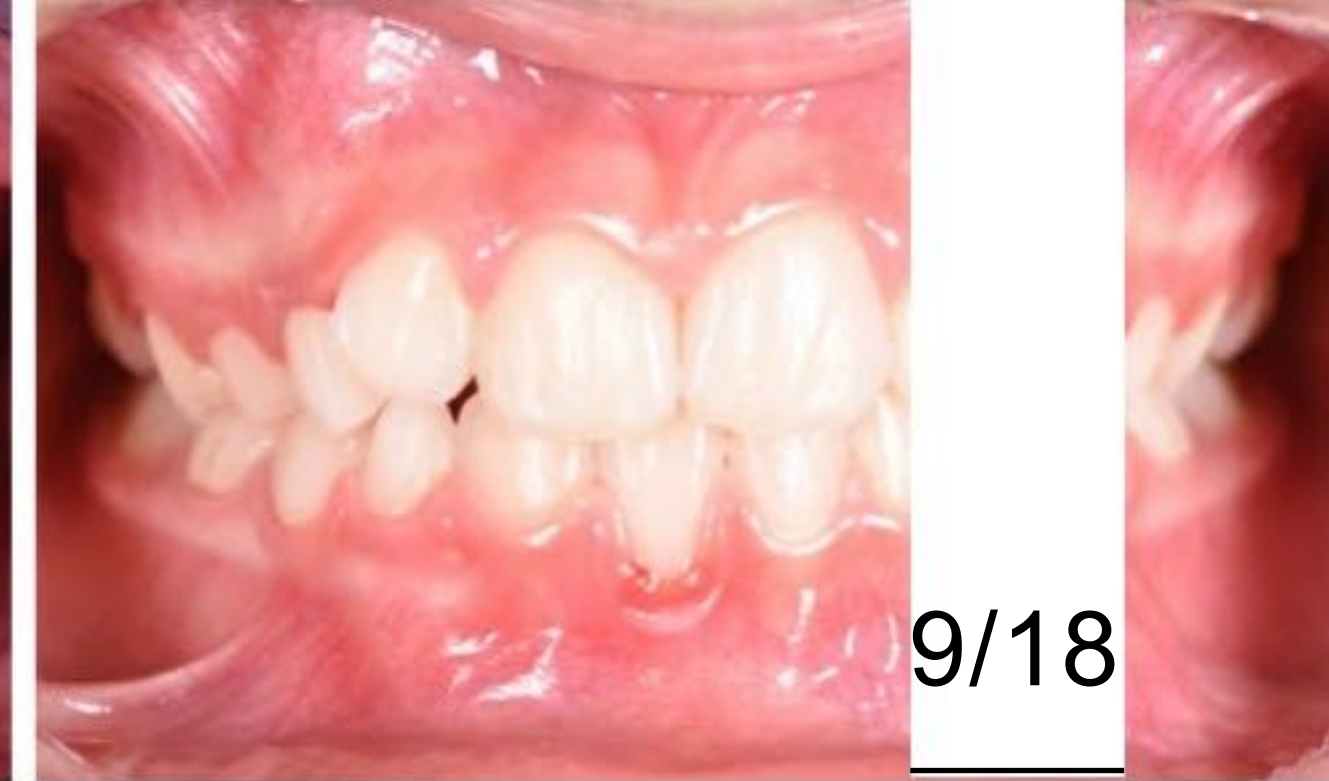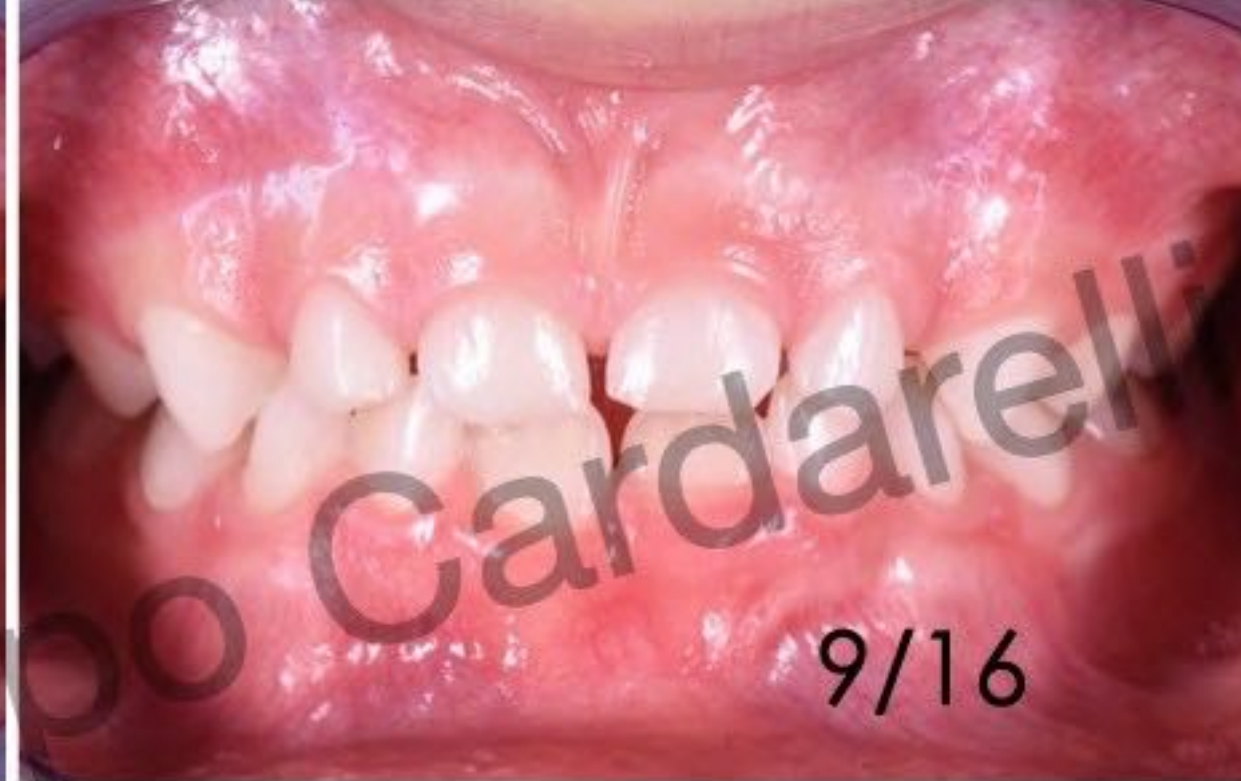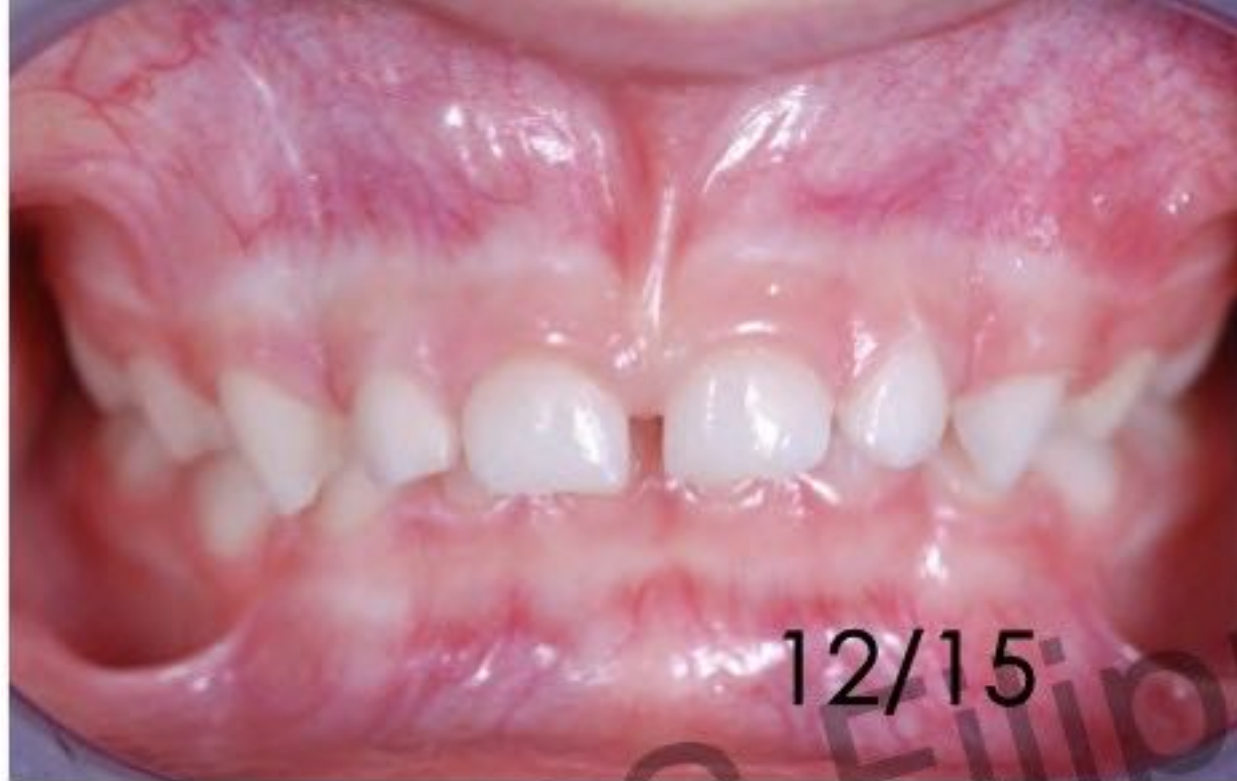12/15

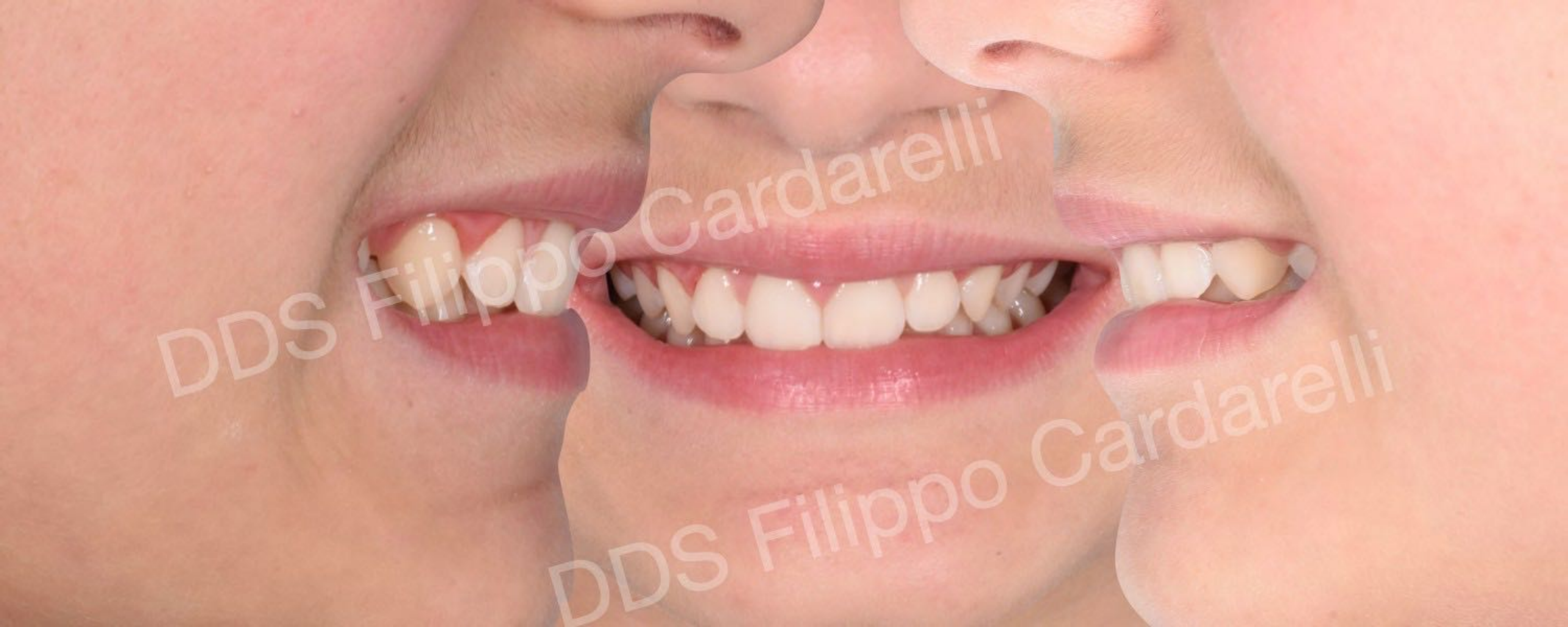

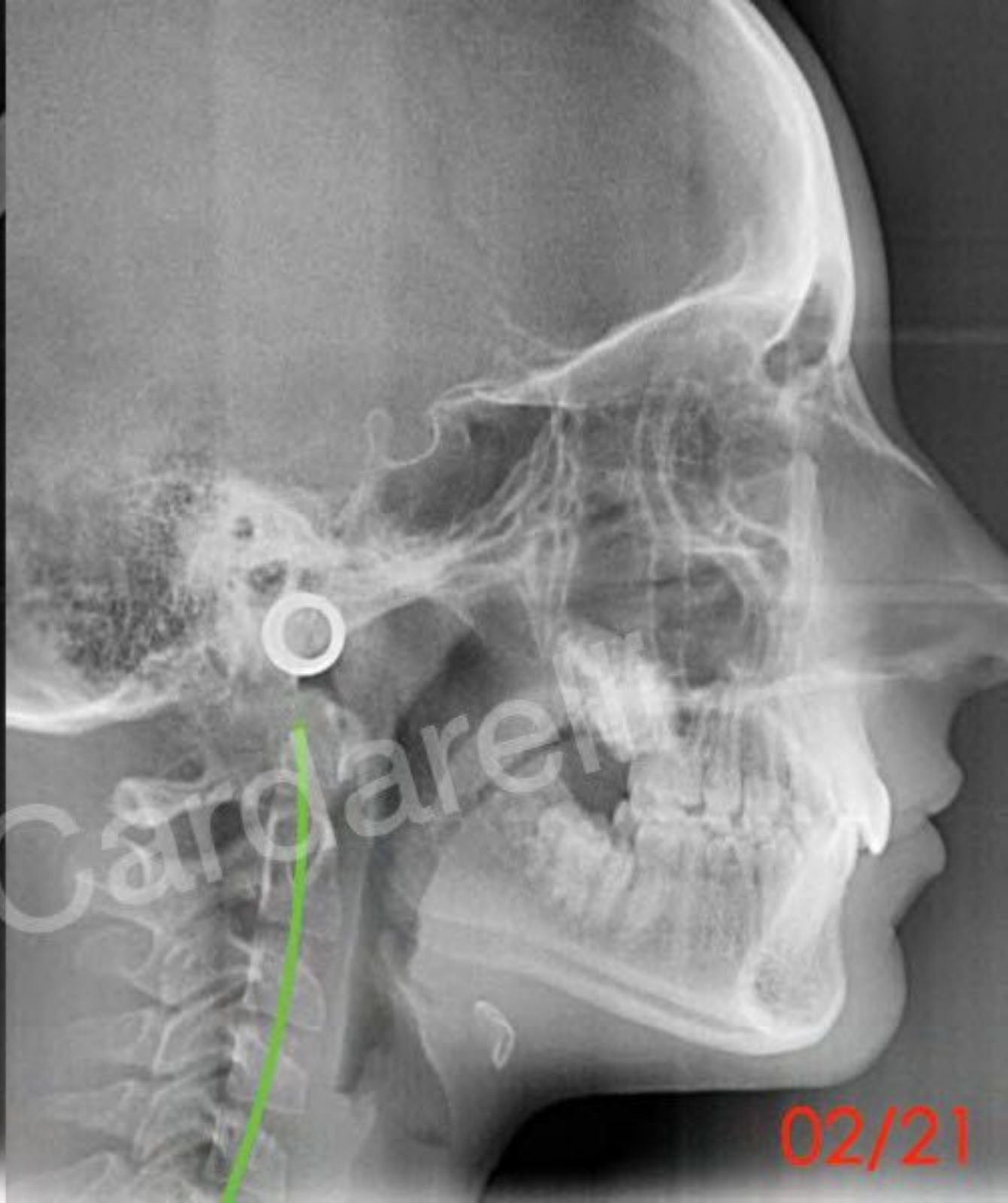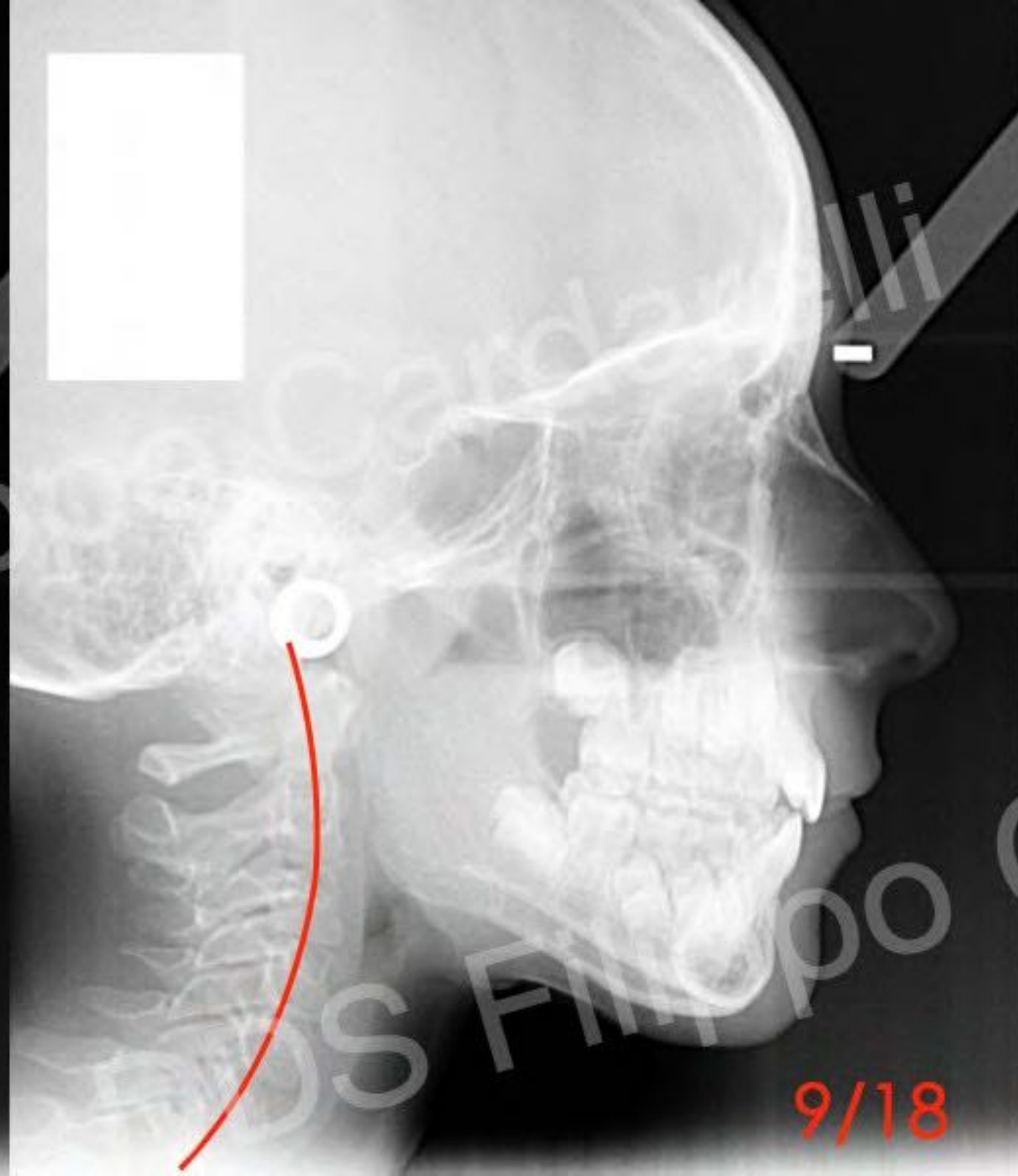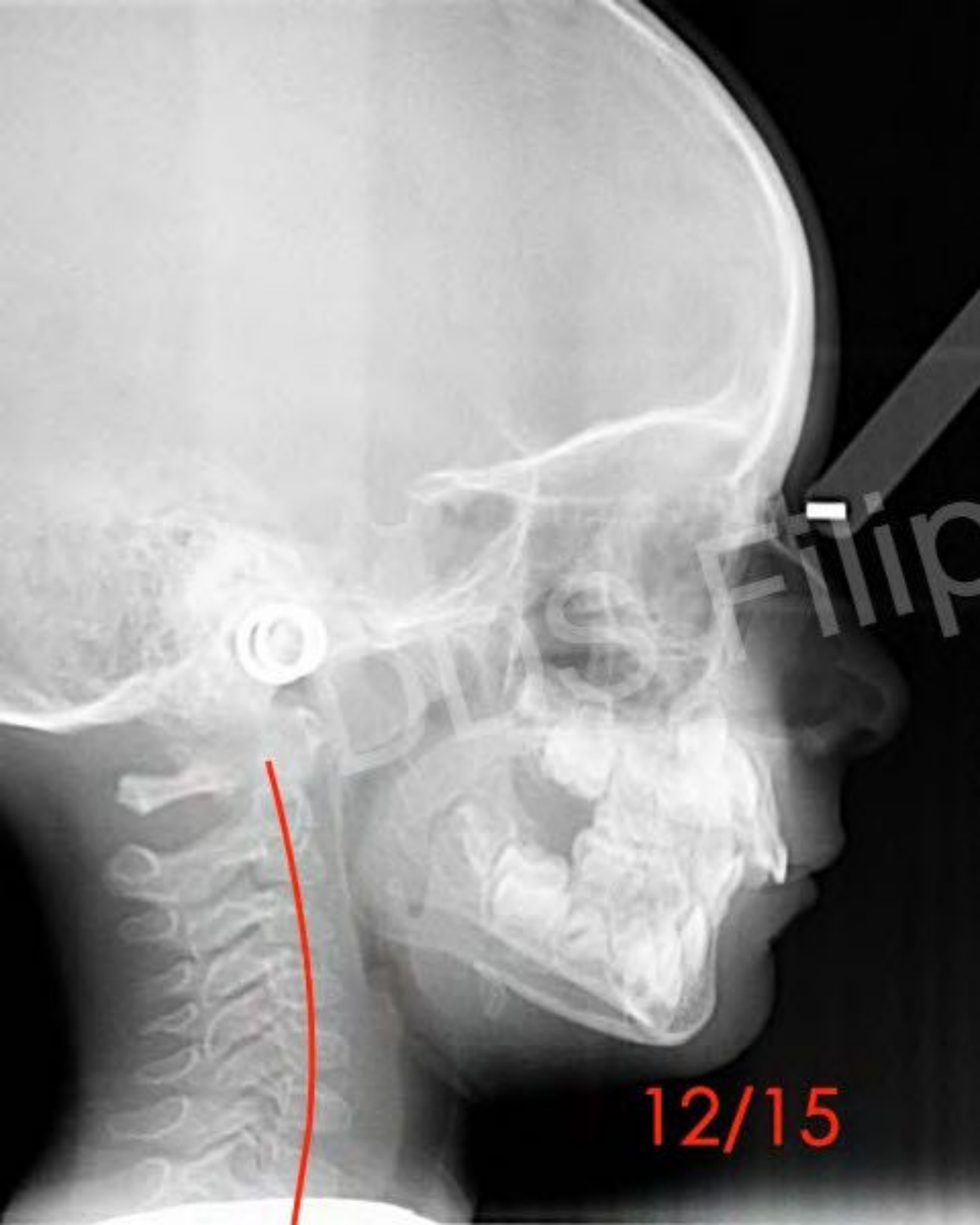
9/18

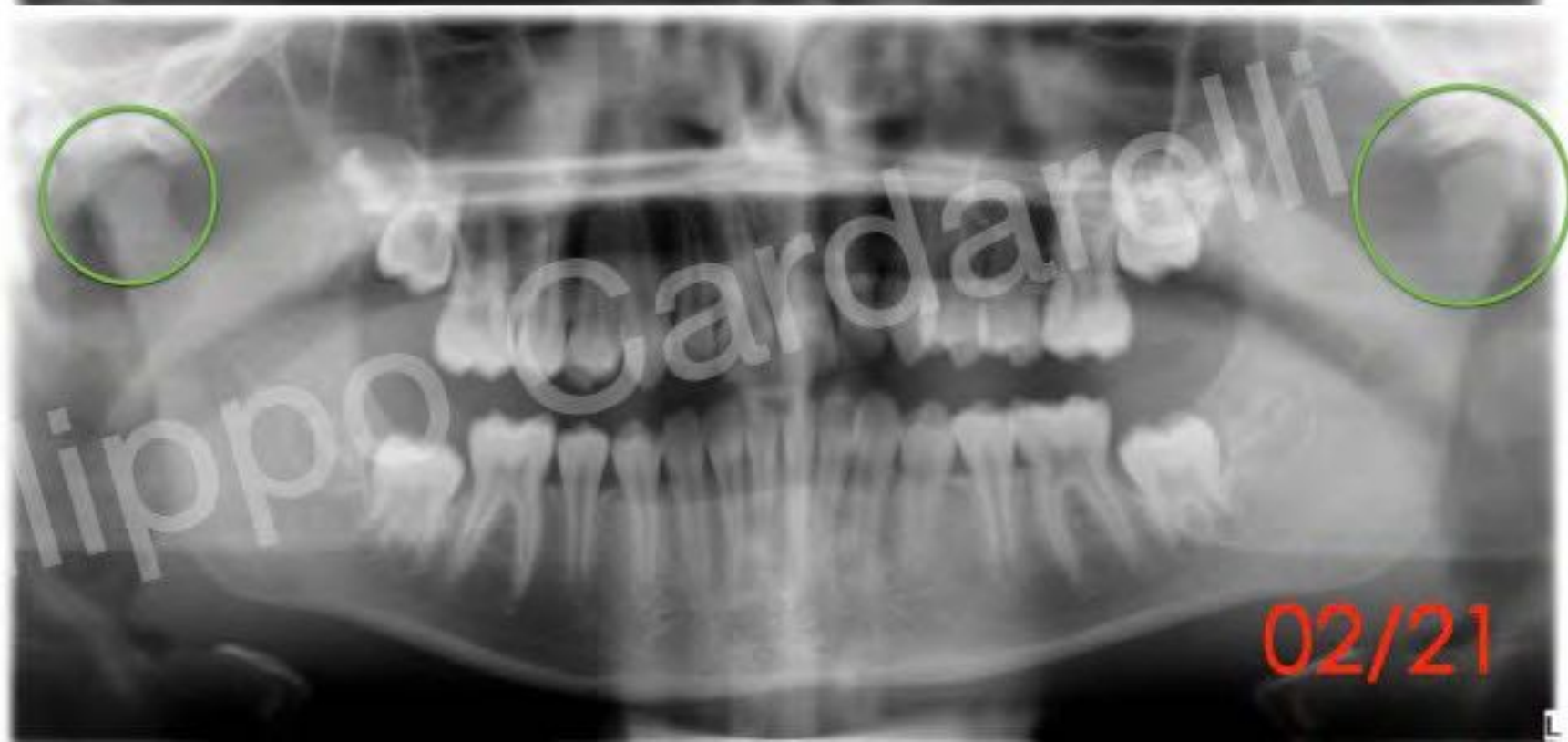
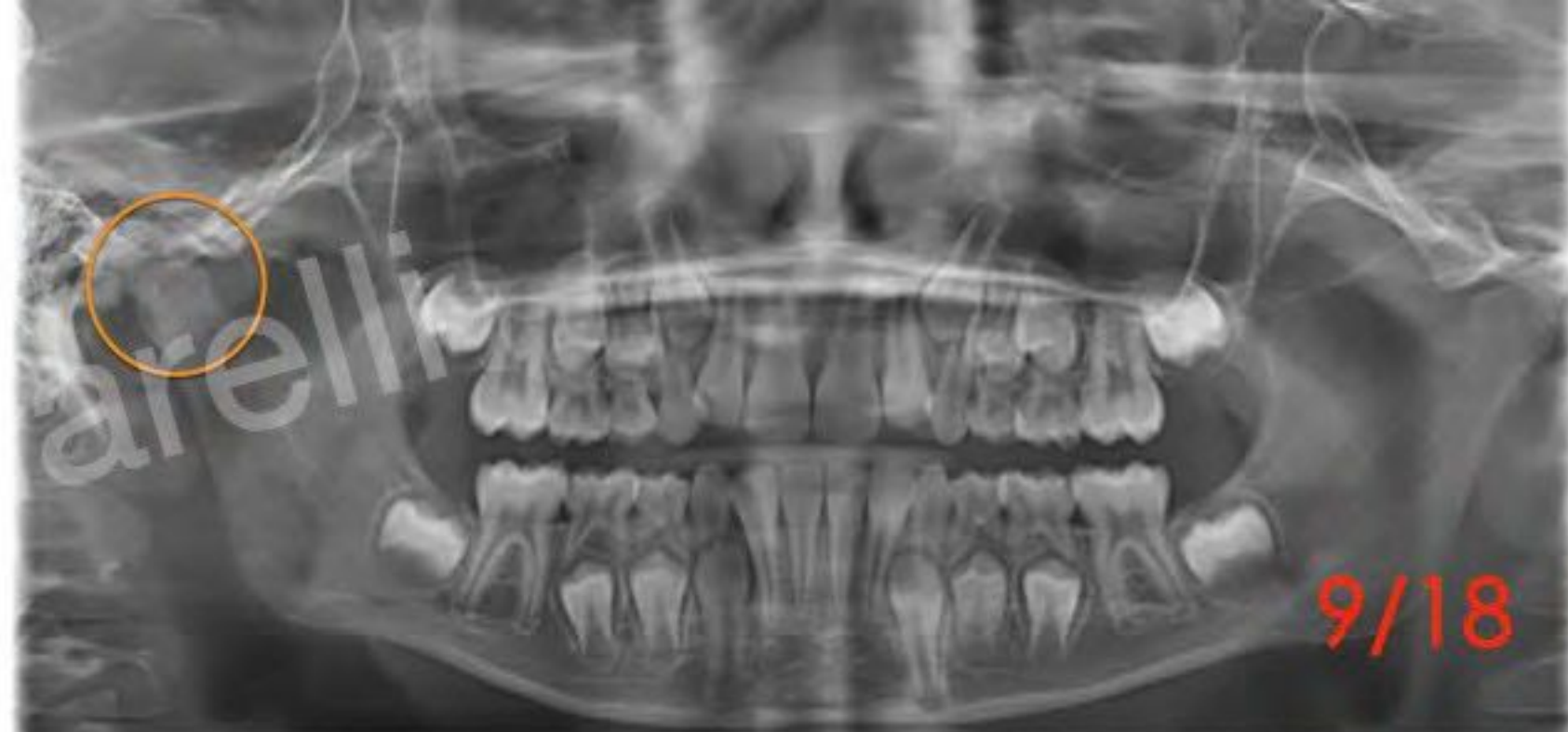
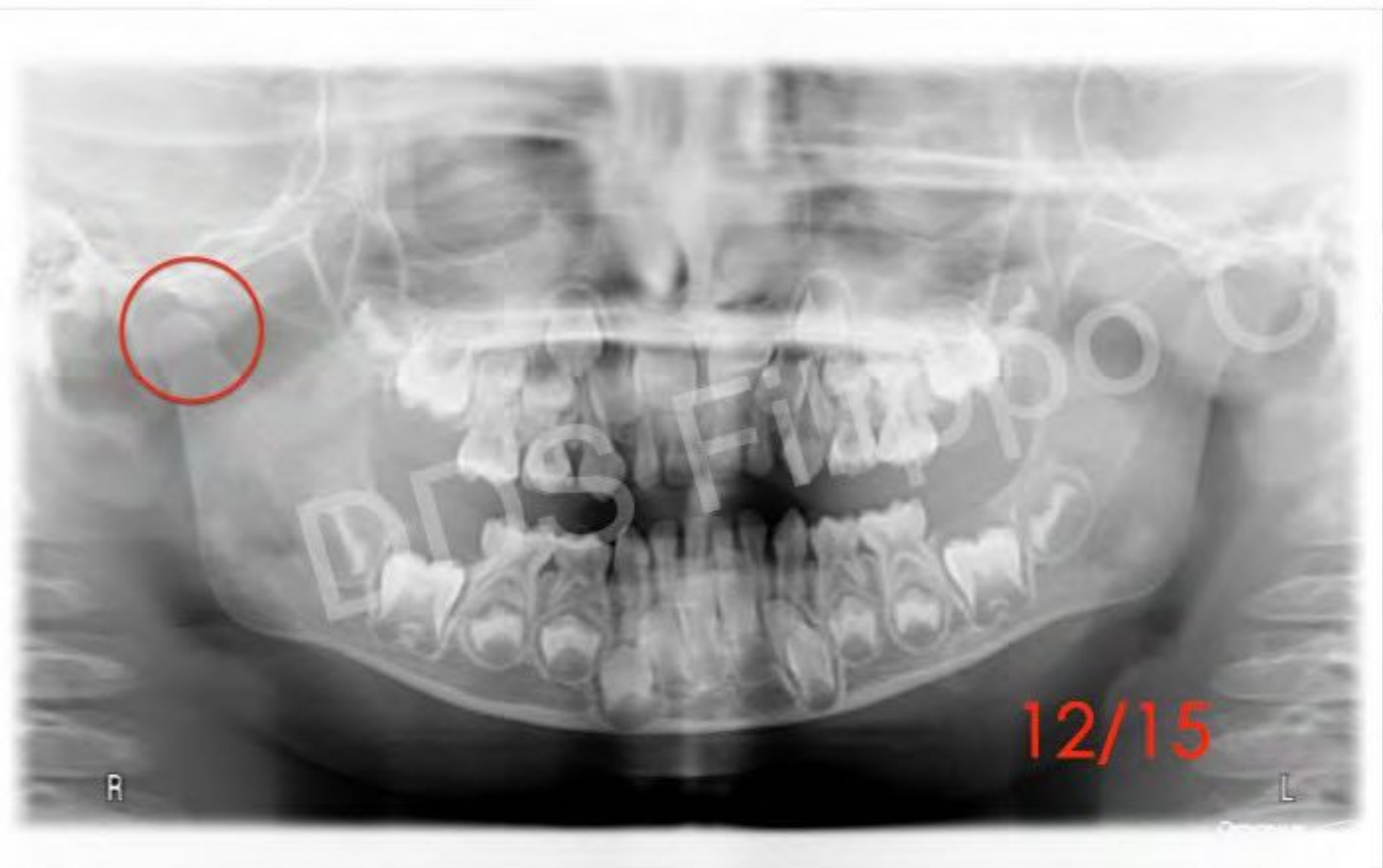02/21









Conclusions

With the achievement of normocclusion through elastodontic therapy, it will also be possible to correct the patient's posture; in some cases, physiotherapy or osteopathy sessions are useful to accelerate and improve therapy. Elastodontic therapy shows the great postural benefit, correcting both occlusal planes and cervical posture.